



Analysis of pediatric fixation equipment with audio-video for chest radiography examinations

Nursama Heru Apriantoro^{1*}, Puji Surpiyono², Heru Prasetyo³, Citra Elisabet Sinarga¹

¹Department of Radiodiagnostic and Radiotherapy, Poltekkes Kemenkes Jakarta II, Indonesia

²PT Adikarya Utama, Medical Devices Distributions, Indonesia

³The National Research and Innovation Agency (BRIN), Indonesia

Abstract

Pediatric patients are generally uncooperative during radiology examinations. Radiographic images can become blurry due to movement. This will cause repeat examinations, thereby significantly increasing radiation exposure, and it can pose significant risks to children, patient families, and radiation workers. The research aims to create and test the effectiveness of a fixation device equipped with Audio-Visual elements for pediatric chest radiography examinations in Anteroposterior and Lateral projections. The experimental method involves developing the fixation device in the Radiodiagnostic Department Laboratory of Poltekkes Kemenkes Jakarta II. The effectiveness of the fixation device is assessed through surveys and interviews involving 66 respondents at hospitals in Jakarta from January to July 2023 during pediatric chest examinations. The average results indicate that the device can be used in hospitals (3.27 ± 0.63), it is safe to use (3.00 ± 0.74), and highly effective (3.17 ± 0.67). The overall average value of 3.16 ± 0.68 suggests that the fixation device is suitable for use in pediatric chest examinations. The images obtained from the anteroposterior and lateral projections optimally describe lung organs, the heart, and blood vessels within the thoracic cavity. Suggestions for further development of the safe device include the addition of leg supports. This pediatric chair can be moved forward/backward, and patient restraints can be used to prevent falling or movement.

This is an open access article under the [CC BY-SA](https://creativecommons.org/licenses/by-sa/4.0/) license



Keywords:

Chest Radiography;
Fixation equipment;
PA/Lateral Projection;
Pediatric;

Article History:

Received: August 28, 2023

Revised: December 4, 2023

Accepted: December 30, 2023

Published: June 2, 2024

Corresponding Author:

Nursama Heru Apriantoro
Department of
Radiodiagnostic and
Radiotherapy, Poltekkes
Kemenkes Jakarta II,
Indonesia
Email: nsheru@gmail.com

INTRODUCTION

One of the common radiological examinations is chest radiography, also known as a chest X-ray. Chest radiography is a diagnostic procedure used to assess abnormalities in the respiratory system, mediastinum, or thoracic bones using X-rays [1, 2, 3]. In pediatric chest radiography, positioning the patient can be challenging due to feelings of fear and anxiety in the radiology room. Pediatric patients may cry and move during the procedure, leading to motion artifacts in the radiographic images or movement unsharpness [3, 4, 5], thus compromising the quality of diagnostic information. This can result in the need for repeated examinations, which can be

a risk to the patient, their family, and radiation staff due to increased radiation exposure, both primary and scatter radiation. Therefore, there is a need for a fixation immobilization device for children to prevent movement and provide comfort [6], thereby minimizing the need for repeat radiographic procedures.

Previous research on using fixation in chest examinations has been reported [7, 8, 9]. However, these previous fixation devices were heavy, constructed with metal, non-mobile, lacked audio-visual elements, and could only separately accommodate a Posteroanterior (PA) or lateral projection. This study aims to create an innovative device for pediatric fixation in radiography examination for both PA and

lateral projections, using audio-visual to enhance the comfort of pediatric patients during chest radiography so that minimize patient movement and image unsharpness, which additional examination can be avoided. The risk of radiation can be reduced.

Anatomy and Pathophysiology of the Chest

The thorax is a cavity composed of the pleural cavity and mediastinum. Within the thoracic cavity are the lungs and the mediastinum, where respiratory and circulatory processes occur. Organs in the thoracic cavity include the lungs, heart, aortic blood vessels, vena cava blood vessels, pulmonary arteries and veins, trachea, bronchi, and oesophagus [10].

Common thoracic abnormalities examined through radiography include pneumonia [11, 12, 13, 14], pleural effusion (accumulation of fluid in the pleural cavity) [15, 16, 17], tuberculosis [18][19], asthma [20][21], chronic bronchitis, and emphysema [22][23], lung cancer [24][25], chronic obstructive pulmonary disease [26][27], bone trauma or fractures [28][29], patients with Covid [30][31], and neonatal disorders [32].

Chest Radiography Technique

Posteroanterior (PA) projection: This technique is performed with the patient lying down or standing, directing the X-rays from the back (posterior) to the front (anterior) of the thoracic organs. The detector or imaging plate is placed in front of the patient. The resulting image provides an anatomical view of the thorax from front to back (AP View). Lateral projection: This technique is carried out by the patient lying down or standing, directing the X-rays from the side (lateral) of the thoracic organs. The resulting image provides a lateral anatomical view of the thorax [3][33].

Thoracic Fixation Device

Fixation devices are aids designed to reduce the need for repeat radiographic examinations and enable radiographers to work efficiently in producing high-quality radiographs [33, 34, 35, 36]. Various types of fixation devices used in radiographic examinations include sandbags, adhesives, head clamps, Sponge Blocks, Compression Bands, Tam-em Boards, Plexiglas's Hold-down Paddles, Posi-Tots, Papoose Boards, and Pigg-o-stat [3].

METHOD

The research design is an experimental study focused on developing a pediatric thoracic radiography fixation device accompanied by audio-visual elements. Quantitative analysis is conducted based on the device's usage in a hospital setting, its safety and comfort, and the effectiveness of its application. Data is collected through surveys involving 66 subjects, including patients (children), patient families, and radiographers working in the hospital's radiology department. Ethical Research Approval has been obtained from the Research Ethics Commission of Poltekkes Kemenkes Jakarta under reference No. LB.02.01/I/KE/30/019/2023 II.

Sampling is done through purposive sampling, where samples are selected based on specific criteria in the radiology department. Inclusion criteria include children aged 1 to 6 years for thoracic radiography examinations or children over three years old who might not be able to stand but can sit properly. Patients are asked to sit in the fixation device during thoracic radiography examinations while observing the audio-visual content, including children's favourite movies. The child's emotional state, including feelings of anxiety, fear, happiness, and cooperative behavior, is observed during the examination.

Questionnaires regarding the fixation device are filled out by both radiographers and patient families using a Likert scale ranging from 1 to 4. The questionnaire data are presented in terms of frequency distribution and central tendencies. Thoracic radiography image quality is evaluated through open-ended interviews with five specialist doctors. Figure 1 shows the research diagram of pediatric chest radiography examination using a fixation device for PA and Lateral projection.

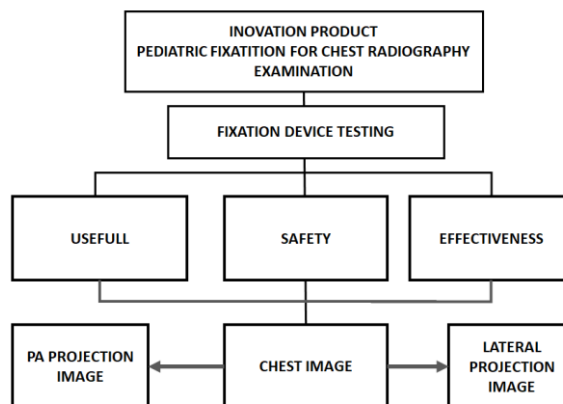


Figure 1. Research Diagram of Pediatric fixation equipment for chest examinations

RESULTS AND DISCUSSION

Design Results

A fixation device for thoracic examinations in both the PA and lateral positions has been developed, as shown in Figure 2. This device includes audio-visual features, an imaging plate/image detector support, a pivotal axis allowing the chair to rotate, raise, and lower, and wheels with locks. The use of a fixation device in a pediatric patient is shown in Figure 3, and the resulting image representation is shown in Figure 4.

The explanation of Figure 2 is as follows:

1. Audio-Visual: Consists of a 10-inch iPad for audio-visual content.
2. Imaging Plate/Image Detector Support: Positions the imaging plate for thoracic radiography to adjust the patient's chest position.
3. Pivot Axis: Enables chair rotation, height adjustment, and lowering.
4. Square Pipe: Functions as both a support for the fixation device and a holder for the wheels.
5. Wheels: Allows easy mobility of the fixation device when not in use.
6. Stainless Steel Hollow Pipe: Provides structural support for the fixation device.

7. Rail Pipe: Facilitates adjustment of the image detector's position.
8. Lock Adjuster Clamp: Locks the image detector in place, preventing movement of the image detector support and maintaining its position.



Figure 2. Pediatric fixation equipment for chest examinations

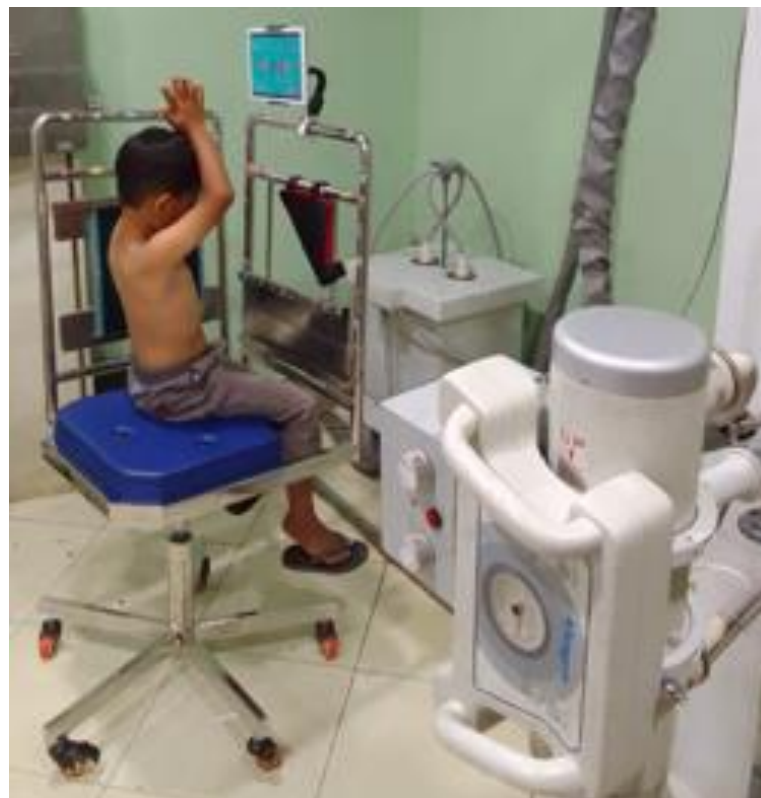

Figure 3. Fixation of a pediatric patient's thoracic radiograph in lateral position

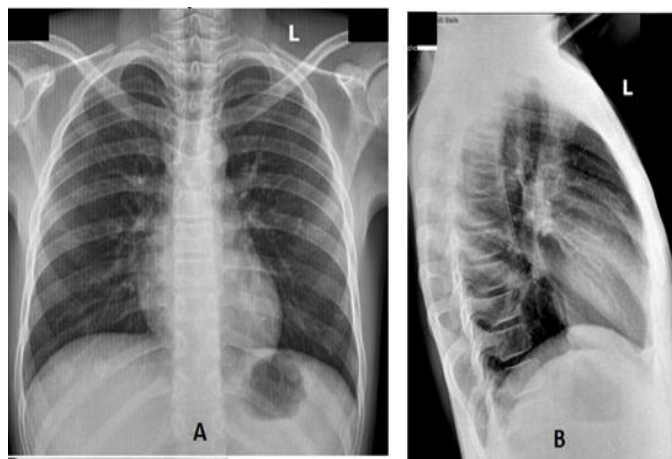


Figure 4. Chest image of a) Postero anterior projection and b) Lateral Projection

The results of the pediatric chest image using fixation, as shown in Figure 4, present thoracic radiographs with both AP and lateral views. The images reveal both lungs, the upper boundary of the lung apices, the appearance of the trachea, aorta arch, cardiac mediastinum, and the uninhibited view of the costophrenic sinus. The symmetry of both lungs is evident from the distance of the costal margin to the vertebral column and the symmetry of the acromioclavicular joint distance.

Additionally, the images show the thoracic vertebrae I-VII, indicating an appropriate kVp setting. In the lateral position, the result is considered optimal when the entire lung is clearly visible, from the lung apex to the costophrenic sinus, the hilum is centred in the radiographic field, the thoracic intervertebral spaces are open (except for scoliosis patients), and the hands do not superimpose on the lungs confusion due to the image axis labels, because figure axis labels are often confusing.

Fixation Device Testing Results

Table 1 shows the results of the questionnaire for testing the pediatric thoracic radiography fixation device with 66 respondents. The highest value from the respondents is at 3.38 ± 0.68 for item 1, indicating that the video device is useful in providing cooperation to patients during examination. The lowest value is 2.88 ± 0.73 at item 8. There are still feelings of fear or anxiety in patients when examinations are carried out. However, for an overall average of 3.16 ± 0.68 , this indicates that, overall, the device is considered usable according to the Likert scale. The Kolmogorov-Smirnov test shows a KS value above the table value of $D_{0.05,66}=0.109$ or a significant P value below 0.05 (95%), indicating that the data is not a Gaussian normal distribution.

Discussion

Designing a fixation device for pediatric thoracic examinations with a 180-degree rotation capability is a significant advancement in medical imaging. The rotation mechanism enables both PA and lateral examinations without requiring the repositioning of the patient. The device should be designed to ensure the comfort and safety of pediatric patients during thoracic examinations. Its materials are non-allergenic, easy to clean, and free from any potential harm to the patient. The addition of audio-visual elements in a pediatric thoracic fixation device helps children relax during the examination.

Based on data from 66 respondents, the fixation device is considered very easy and practical to use (3.27 ± 0.67), significantly aids in facilitating work (3.24 ± 0.63), increases work comfort (3.20 ± 0.64), and supports thoracic examination procedures (3.26 ± 0.56), useful of video for providing cooperation to patients (3.38 ± 0.63), and chest radiography image (3.27 ± 0.60). Overall, the average value of the device's usability is (3.34 ± 0.58). The fixation device was designed to simplify thoracic examinations and reduce the need for repeated imaging, especially for pediatric patients, and is aimed at minimizing excessive movement during the procedure. Pediatric radiology often requires fixation devices to avoid movement and hold the child during examination. Excessive movement can affect the quality of the images. Such devices are compulsory to ensure the safety and accuracy of the examinations.

Movement unsharpness is a common issue in pediatric radiology, particularly in chest examinations, and can lead to suboptimal images due to pediatric movement. This motion can cause image artifacts or blur, making it difficult to evaluate the results and potentially leading to misdiagnosis.

Table 1. Fixation Device Testing Questionnaire

No	Criteria	N	Mean	SE	SD	KS	
Usage of Device in Hospitals							
1	This fixation device is easy and practical to use for pediatric thoracic radiography in both PA and lateral positions	66	3.27	0.08	0.67	0.26	
2	This device assists you in your work, especially for pediatric thoracic radiography in both PA and lateral positions	66	3.24	0.08	0.63	0.30	
3	Using this device makes you feel more comfortable at work	66	3.20	0.08	0.64	0.30	
4	This device is beneficial in supporting pediatric thoracic radiography examinations	66	3.26	0.07	0.56	0.36	
5	Using audio video is useful in providing cooperation to patients	66	3.38	0.08	0.63	0.29	
6	Optimal Radiographic Image Results	66	3.27	0.07	0.60	0.33	
Average Value of Device Usage			3.27	0.03	0.63	0.30	
Device Safety							
7	This device is safe and not harmful and does not cause pain or allergies	66	3.27	0.07	0.60	0.23	
8	Patients do not feel fearful or anxious when using this device	66	2.88	0.09	0.73	0.26	
9	This device is very sturdy and strong	66	3.05	0.09	0.73	0.26	
Average Value of Safety			198	3.00	0.05	0.74	0.25
Device Effectiveness							
10	Using this device makes your work more practical/easier	66	3.24	0.08	0.68	0.28	
11	Using this device makes your work more efficient	66	3.26	0.09	0.71	0.26	
12	This device is inexpensive and affordable	66	3.00	0.07	0.61	0.32	
Average Value of Effectiveness			198	3.17	0.05	0.67	0.28
Overall Average			726	3.16	0.03	0.68	0.27

The utilization of a fixation device, such as a chair that a child sits on a chair while comfortably watching audio-visual content, can facilitate the imaging process in the PA and Lateral position.

The device can be rotated 90 degrees to conduct lateral examinations without significant patient repositioning, which means minimal patient movement during examination. Projections from PA to Lateral usually use special equipment that allows for patient positioning to perform different chest images. The ability to rotate a device for lateral examinations with minimal patient repositioning can be advantageous in reducing patient discomfort and the need for extensive adjustments between different projection procedures. This flexibility can contribute to a more efficient workflow and improved patient experience during medical imaging examinations.

However, improvements are needed for the device, particularly regarding its size (40%, it was interview data collected from respondents). The device is still considered a relatively big size for the radiology room. The correspondents recommended a more compact and foldable design for the fixation device. More appealing coloring (21%). According to research, children respond positively to bright colors, such as pink, blue, and red, and have negative emotions towards dark colors, such as brown, black, and

gray. Therefore, using more appealing and bright colors, such as primary colors, may be recommended to make products more attractive to children. The use of sticker accessories can enhance the experience for children during medical procedures (3%). It is a common practice in pediatric medical settings to use stickers as a form of distraction and comfort for children during various procedures, so the funny cartoon sticker makes the experience more enjoyable for the children. Another important consideration is the positioning of the audio video (12%), as a video display not aligned with the patient's eyes can cause discomfort when patients strain to view the content. Ensure that the video is positioned at least an arm's length away from the patient and at eye level to avoid eye strain, neck strain and discomfort.

In terms of safety and comfort, the device is considered safe and does not cause pain/allergies (3.27 ± 0.60), does not induce fear or anxiety (2.88 ± 0.73) and is very sturdy (3.05 ± 0.73). The average value of the safety device is 3.00 ± 0.74 . For comfort during the examination and to make it easier for the radiographer to visualize chest imaging, ensure that the fixation device was made from materials that do not cause pain or allergies and provide a feeling of the child's comfort during the chest procedure. This device has benefits that far outweigh the risks.

The tools made should provide a sense of safety and not cause fear or anxiety. Tools are made in shapes that can help children relax and distract them from any anxiety they may experience. The parent can also be present to comfort the child during the procedure. By implementing these strategies, the fixation can help create a comfortable and positive environment for children undergoing X-ray procedures.

The Fixation Tool is made very sturdy. It has been tested for its ability to withstand the force and pressure exerted by the patient during its use. In addition, Although the robustness of this tool has been proven, strict testing and quality control measures must be carried out, especially regarding its safety and reliability. Suggesting the device is relatively safe to use. However, improvements are necessary, particularly in terms of adhesive use for hands, feet, and chest (53%). These adhesives aim to immobilize the patient and ensure safety during exposure, preventing movement that could blur the image. Additionally, foot support (19%) is recommended for added comfort during sitting. Lowering the chair height (12%) is also suggested to reduce fear and enhance patient comfort. The device's design, including a soft seat (15%), provides a painless experience for the patient. There is room for improvement based on respondent feedback regarding safety, and innovations to enhance safety are recommended. Nevertheless, the device has been designed to be robust, safe, and comfortable for pediatric thoracic radiography.

Effectiveness means achieving expected outcomes or goals using a simple, cost-effective device. The device's effectiveness is evident in its practical and easy usage (3.24 ± 0.68), efficiency improvement (3.26 ± 0.71), and affordability (3.00 ± 0.61). The average value of device effectiveness is 3.27 ± 0.62 , concluding that the device is effective for pediatric thoracic examinations. Pediatric fixation is useful for stabilizing patients in chest X-ray examination, with radiographers being satisfied with the performance and usability of the devices. These fixation tools and techniques demonstrate the practicality and are easy to use. The study does suggest that fixation can be an effective treatment option for pediatric chest X-rays. The affordability of fixation is evident in chest X-ray applications, a low-cost technique because the technique is straightforward to use and affordable, not requiring a long examination period. These findings demonstrate that fixation methods can be affordable, making them cost-effective in various X-ray examinations.

However, improvements are needed regarding the fixed seating (32%), which should be adjustable to move forward and backward. This adjustment would enable the subject to be as close as possible to the detector for optimal imaging. Another important aspect is image quality. Through direct interviews with radiology specialist doctors, it was found that 100% of them stated there were no issues with the thoracic images. All experts concurred that the images produced were optimal, fulfilling the criteria for a proper pediatric thoracic radiography projection.

CONCLUSION

Based on the questionnaire analysis and interviews, the fixation device proves usable, safe, and practical. The imaging criteria are optimally visualized in both PA and lateral positions. Special attention should be given to the design, including the use of secure fasteners, footrests, comfortable video positioning, and the device being made as light and sturdy as possible to advance the product's innovation and development within a business context

ACKNOWLEDGMENT

We extend our gratitude to the Director of Poltekkes Kemenkes Jakarta II for providing for this research. We also thank the radiographers and staff at RSUD DKI Jakarta, RS. Mery and other hospitals for their contributions. A special thanks go to Puji Supriono and PT Adikarya Utama staff for their in-kind and cash assistance for the device's construction and placement in his hospital.

REFERENCES

- [1] W. R. Webb and C. B. Higgins, *Thoracic Imaging Pulmonary and Cardiovascular Radiology*, Wolters Kluwer: London, UK, 2016.
- [2] M. Prakash and M. S. Sandhu, "Chest Radiography and Sonography: Techniques and Anatomy," in *Diagnostic Radiology: Chest and Cardiovascular Imaging*, A. Garg; Arun K. Gupta; and N. Khandelwal, Eds., New Delhi: Jaypee Brothers, Medical Publishers, India, vol. 46, no. 4, pp 305-316 2018, doi: 10.1067/j.cpradiol.2016.12.003.
- [3] J. P. Lampignano and L. E. Kendrick, *Bontrager's Handbook of Radiographic Positioning and Techniques*, 9th. Ed. St Louis: Elsevier, 2018.
- [4] C. M. Hayre and William A. S. Cox, *General Radiography: Principles and Practices*, Boca Raton: CRC Press, 2020.

- [5] B. W. Long, D.F. Eugene, and A. E. Ruth, *Radiography Essentials for Limited Practice*. St Louis: Elsevier, 2021.
- [6] D.F. Eugene, B. W. Long, and J. B. Barbara, *Merrill's Atlas of Radiographic Positioning and Procedures*, vol. 3, 15th Ed. Elsevier, 2023.
- [7] S. Masrochah, Y. Kartikasari, and A. S. Wibowo, "Fixation Design Device on Child Support Radiographs Patient Safety and Safety Radiation," *Jurnal Riset Kesehatan*, vol. 2, no. 1, pp. 269–276, 2013, doi: 10.31983/jrk.v2i1.158
- [8] E. Klavs, D. Pašagić, and N. Kotar, "Radiation Protection in Pediatric Radiography – Introducing Some Immobilization and Protection Equipment," *Paediatrics Today*, vol. 12, no. 1, pp. 81–86, 2016, doi: 10.5457/p2005-114.139.
- [9] M. M. U. D. Malik et al., "Challenges faced by a radiographer during pediatric imaging," *Journal of Xi'an Shiyou University*, vol. 18, no. 9, pp. 458-465, 2022.
- [10] R. Koshi, *Cunningham's Manual of Practical Anatomy*, vol. 2, Thorax and Abdominal. New York: Oxford University Press, 2017.
- [11] D. R. Ramponi, C. Baker, and D. R. Ramponi, "Chest X-Ray Findings in Patients With COVID-19 Pneumonia," *Advanced Emergency Nursing Journal*, vol. 44, no. 3, pp. 206–2017, 2022, doi: 10.1097/TME.0000000000000418.
- [12] J. Rueckel et al., "Pneumothorax detection in chest radiographs: optimizing artificial intelligence system for accuracy and confounding bias reduction using in-image annotations in algorithm training," *European Radiology*, vol. 10, pp. 7888 - 7900, 2021, doi: 10.1007/s00330-021-07833-w.
- [13] J.-H. Yan, N. Yu, Y.-H. Wang, Y.-B. Gao, and L. Pan, "Lung ultrasound vs chest radiography in the diagnosis of children pneumonia," *Medicine*, vol. 99, no. 50, p. e23671, 2020, doi: 10.1097/MD.00000000000023671.
- [14] X. Wang et al., "Automatic Segmentation of Pneumothorax in Chest Radiographs Based on a Two-Stage Deep Learning Method," in *IEEE Transactions on Cognitive and Developmental Systems*, vol. 14, no. 1, pp. 205-218, March 2022, doi: 10.1109/TCDS.2020.3035572
- [15] L. Zhou et al., "Detection and Semiquantitative Analysis of Cardiomegaly, Pneumothorax, and Pleural Effusion on Chest Radiographs," *Radiology Artificial Intelligence*, vol. 3, no. 4, p. e200172, 2021, doi: 10.1148/ryai.2021200172.
- [16] P. Y. Chen, C. H. Lin, C. D. Kan, N. S. Pai, W. L. Chen, and C. H. Li, "Smart Pleural Effusion Drainage Monitoring System Establishment for Rapid Effusion Volume Estimation and Safety Confirmation," *IEEE Access*, vol. 7, pp. 135192–135203, 2019, doi: 10.1109/ACCESS.2019.2941923.
- [17] E. S. M. Mohamed, "In diagnosis of pleural effusion and pneumothorax in the intensive care unit patients: Can chest us replace bedside plain radiography," *Egyptian Journal of Radiology and Nuclear Medicine*, vol. 49, no. 2, pp. 346–351, 2018, doi: 10.1016/j.ejrn.2018.02.006.
- [18] C. C. Heuvelings et al., "Chest ultrasound compared to chest X-ray for pediatric pulmonary tuberculosis," *Pediatric Pulmonology*, vol. 54, pp. 1914–1920, 2019, doi: 10.1002/ppul.24500.
- [19] X.-F. Cao, Y. Li, H.-N. Xin, H.-R. Zhang, M. Pai, and L. Gao, "Application of Artificial Intelligence in Digital Chest Radiography Reading for Pulmonary Tuberculosis Screening," *Chronic Diseases and Translational Medicine*, vol. 7, pp. 35–40, 2021, doi: 10.1016/j.cdtm.2021.02.001
- [20] E. H. Allie et al., "ED chest radiography for children with asthma exacerbation is infrequently associated with change of management," *The American Journal of Emergency Medicine*, vol. 36, no. 5, pp. 769–773, 2018, doi: 10.1016/j.ajem.2017.10.009
- [21] A. H. Mustopa, "Assistancy in Nursing Care of Medical Surgical Nursing for Patients with Respiratory System Disorder (Asthma) in Mawar Room, General Hospital of Dr. Soekardjo Tasikmalaya," *Kolaborasi Inspirasi Masyarakat Madani*, vol. 002, No. 001, pp. 6–26, 2021.
- [22] Ö. Çapraza and A. Deniz, "Assessment of hospitalizations from asthma, chronic obstructive pulmonary disease and acute bronchitis in relation to air pollution in İstanbul, Turkey," *Sustainable Cities and Society*, vol. 72, 2021, doi: 10.1016/j.scs.2021.103040
- [23] J. Qin et al., "Differential coexpression networks in bronchiolitis and emphysema phenotypes reveal heterogeneous mechanisms of chronic obstructive pulmonary disease," *Journal of Cellular and Molecular Medicine*, vol. 23, pp. 6989–6999., 2019, doi: 10.1111/jcmm.14585.
- [24] C. Wang, A. Elazab, J. Wu, and Q. Hu, "Lung nodule classification using deep feature fusion in chest radiography," *Computerized Medical Imaging and*

- Graphics*, vol. 57, pp. 10-18, 2017, doi: 10.1016/j.compmedimag.2016.11.0
- [25] A. L. Oliver, "Lung cancer: Epidemiology and screening," *Surgical Clinic North America*, vol. 102, no. 3, pp. 335–344, 2022, doi: 10.1016/j.suc.2021.12.001.
- [26] R. M. Burkes and J. F. Donohue, "An update on the global initiative for chronic obstructive lung disease 2017 guidelines with a focus on classification and management of stable copd," *Respiratory Care*, vol. 63, no. 6, pp. 749–758, 2018, doi: 10.4187/respcare.06174.
- [27] H. Whittaker et al., "Frequency and severity of respiratory infections prior to COPD diagnosis and risk of subsequent postdiagnosis COPD exacerbations and mortality: EXACOS-UK health care data study," *Thorax*, vol. 78, no. 8, pp. 760-766, 2022, doi: 10.1136/thorax-2022-219039.
- [28] M. Awais, B. Salam, N. Nadeem, A. Rehman, and N. U. Baloch, "Diagnostic Accuracy of Computed Tomography Scout Film and Chest X-ray for Detection of Rib Fractures in Patients with Chest Trauma: A Cross-sectional Study," *Cureus*, vol. 11, no. 1, pp. 1–16, 2019, doi: 10.7759/cureus.3875.
- [29] M. Piastra, V. Ferrari, T. C. Morena, E. Picconi, and G. Conti, "Delayed tension hemothorax after chest trauma in children," *Pediatric Pulmonology*, vol. 57, no. 7, pp. 1818–1819, 2022, doi: 10.1002/ppul.25947.
- [30] A. Kerpel et al., "Diagnostic and prognostic value of chest radiographs for COVID-19 at presentation," *Western Journal of Emergency Medicine*, vol. 21, no. 5, pp. 1067–1075, 2020, doi: 10.5811/westjem.2020.7.48842.
- [31] L. Di Meglio, S. Carriero, P. Biondetti, B. J. Wood, and G. Carrafiello, "Chest imaging in patients with acute respiratory failure because of coronavirus disease 2019," *Current Opinion in Critical Care*, vol. 28, no. 1, pp. 17–24, 2022, doi: 10.1097/MCC.0000000000000906
- [32] H.-K. Yoon, "Interpretation of Neonatal Chest Radiography," *Journal of the Korean Society of Radiology*, vol. 74, no. 5, pp. 279–290, 2016, doi: 10.3348/jksr.2016.74.5.279.
- [33] B. W. Long, Jeannean H. Rollins, and Barbara J. Smith, *Merrill's Atlas of Radiographic Positioning and Procedures*, St Louis: Elsevier, 2019.
- [34] S.-J. Yoo, C. MacDonald, and P. Babyn, *Chest Radiographic Interpretation in Pediatric Cardiac Patients*, New York: Thieme Medical Publisher, 2010.
- [35] M. K. I. Ahmad et al., "Closed-loop Functional Electrical Stimulation (FES) – cycling rehabilitation with phase control Fuzzy Logic for fatigue reduction control strategies for stroke patients," *SINERGI*, vol. 28, no. 1, pp. 63-74, 2024, doi: 10.22441/sinergi.2024.1.007
- [36] R. Muwardi, J. M. R. Permana, H. Gao, M. Yunita, "Human Object Detection for Real-Time Camera using Mobilenet-SSD," *Journal of Integrated and Advanced Engineering (JIAE)*, vol. 3, no. 2, pp. 141-150, 2023, doi: 10.51662/jiae.v3i2.108